

Mieke Moerman · Hubert Vermeersch  
Philippe Heylbroeck

## A simple surgical technique for tracheoesophageal fistula closure

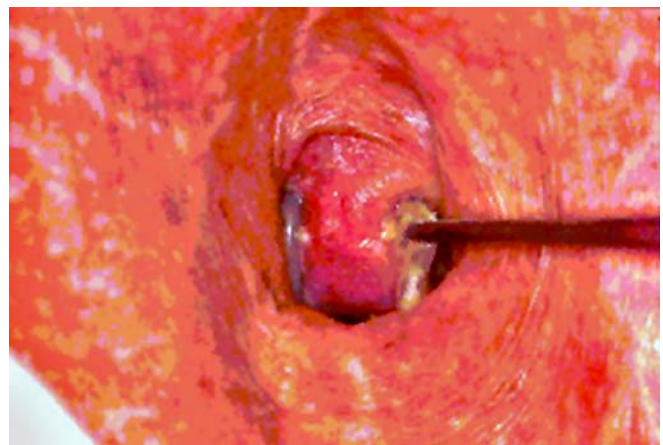Received: 19 May 2003 / Accepted: 8 September 2003 / Published online: 24 October 2003  
© Springer-Verlag 2003

**Abstract** Placement of a voice device in a tracheoesophageal fistula provides successful speech rehabilitation after total laryngectomy. However, in the long term, removal of the voice device and permanent closure of the fistula is sometimes necessary. This paper presents and evaluates a simple surgical technique for primary closure of tracheo-esophageal fistulae. We retrospectively review 12 laryngectomees who received this technique of primary closure from 1997 to 2000. In 58% of the patients, permanent fistula closure could be obtained. Six patients (50%) healed primarily; in one patient (8%) the residual fistula opening healed secondarily. Four patients (33%) needed a second surgical procedure, and in one patient (8%) inserting a new speech prosthesis obliterated the residual fistula. Radiotherapy seems to compromise wound healing and therefore may be considered as a contraindication. Complications such as tracheal stenosis, tissue necrosis and pneumonia, etc., did not occur.

**Keywords** Tracheoesophageal fistula · Laryngectomy · Voice prosthesis

### Introduction

Primary tracheoesophageal (TE) puncture and placement of a voice device result in successful speech rehabilitation after total laryngectomy. However, in the long term, ex-



**Fig. 1** Exofytic tissue growth

trusion of the prosthesis or, contrarily, widening of the fistula, can occur with leakage through the TE fistula and pneumonia as a consequence (Fig. 1). Brasnu et al. report enlargement of the tracheo-esophageal fistula and leakage in 46% of their study population [1]. Several conservative procedures such as silver nitrate application, teflon, collagen or fat injection have been tried to resolve the latter problem. However, these techniques do not consistently provide long-term satisfaction [1, 2, 3]. Therefore, permanent surgical closure of the fistula becomes mandatory. Various authors advise the use of pedicled or free flaps to avoid fistula recurrence [4, 5, 6, 7]. Reviewing the literature, we only found one report concerning primary closure without the need for additional tissue [8]. We describe a simple surgical technique and the surgical and functional outcome in 12 patients operated on from 1997 to 2000.

### Subjects and methods

#### Patients

From 1997 to 2000, 12 patients underwent tracheo-esophageal fistula closure using the described technique at the ENT and Head

Both first authors contributed equally to this paper.

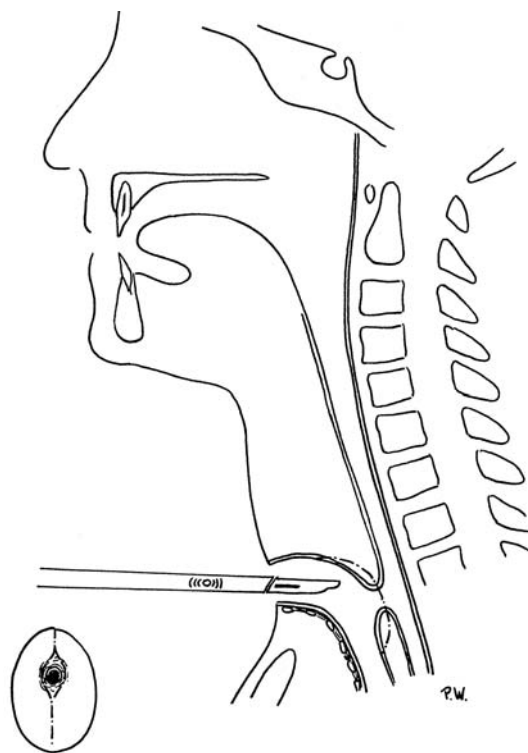
M. Moerman  
Institute of Phoniatrics, University Medical Centre Utrecht,  
Utrecht, The Netherlands

H. Vermeersch · P. Heylbroeck  
Department of ENT and Head and Neck Surgery,  
Ghent University Hospital, Ghent, Belgium

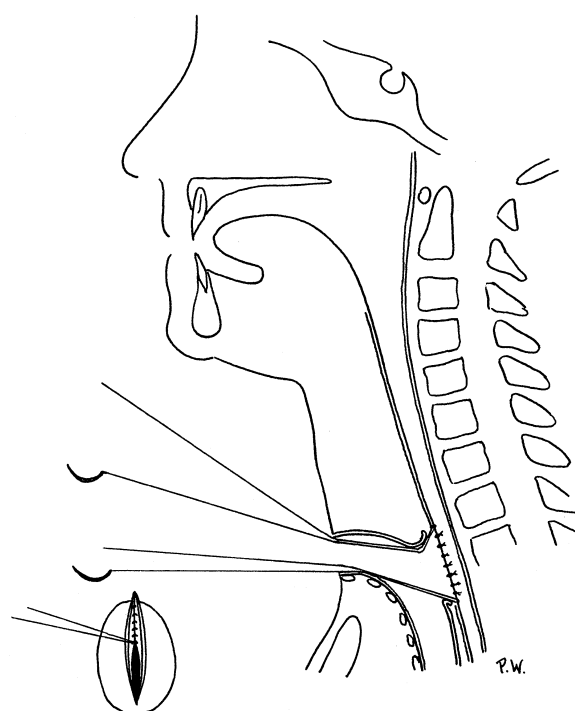
M. Moerman (✉)  
Min.Liebaertlaan 63, 8500 Kortrijk, Belgium  
Tel.: +32-56-252767  
e-mail: mieke.moerman@tiscali.be

**Table 1** Patient characteristics. *TE* tracheo esophageal speech, *exofytic growth* proliferative tissue growth, *pulmon dis* pulmonary disease (chronic obstructive lung disease)

Patients (All males)	Date of Birth (Day/month/year)	Date of laryngectomy (Day/month/year)	Placement (primary/secondary)	Reason for prosthesis removal
P1	18/03/41	19/01/99	Primary	Patient did not use TE
P2	08/04/31	01/94	Secondary	Enlargement of TE fistula
P3	05/09/23	08/97	Primary	Patient did not use TE
P4	21/06/36	25/03/98	Primary	Enlargement of TE fistula
P5	15/03/35	27/10/97	Primary	Enlargement of TE fistula
P6	26/02/46	13/05/95	Primary	Exofytic growth
P7	19/01/28	17/03/97	Primary	Enlargement of TE fistula
P8	28/01/29	20/05/97	Primary	Pulmon dis + no TE speech
P9	17/07/25	09/01/98	Primary	Obstructive dysphagia
P10	15/05/38	26/06/93	Primary	Exofytic growth
P11	31/08/29	06/04/98	Primary	Enlargement of TE fistula
P12	30/04/22	01/96	Primary	Patient did not use TE



**Fig. 2** Outline of the incision around the fistula in favor of the tracheal lining



**Fig. 3** Closure of the first esophageal layer, separated inverted sutures

and Neck Surgery Department of the Ghent University Hospital, Belgium. Surgery was performed on explicit demand of the patients by two independent surgeons (MM and HV) after failure of conservative treatment.

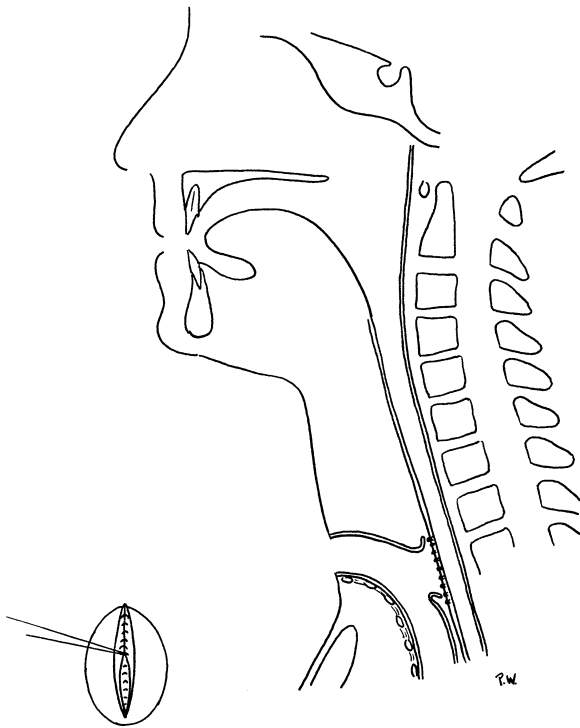
In one patient who had received a tracheo-esophageal voice prosthesis by secondary placement for obtaining a superior voice quality compared to his esophageal voice, the prosthesis was removed for reasons of little benefit in voice quality and objections about the intensive cleansing procedure and daily hygiene. For this, and because of leakage around the prosthesis, he asked for removal of the prosthesis and closure of the fistula.

In more recent laryngectomy procedures, primary placement of the prosthesis has been standard procedure. Symptoms of reaction were the main cause for prosthesis removal (58%). This can present as an exofytic tissue growth with expulsion of the prosthesis as a consequence, or as a widening of the tracheo-esophageal fis-

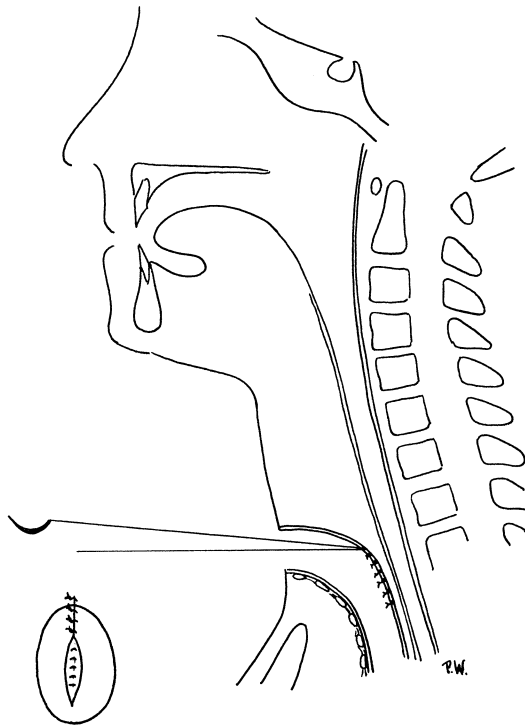
tula with loosening of the prosthesis and secondary leakage around the prosthesis. Other reasons for prosthesis removal were disuse of the TE speech (33%) and obstructive swallowing impairment (8%) (Table 1).

#### Surgical technique

The procedure is performed under general anaesthesia with high frequency jet ventilation. As cotton gauze blocks the tracheal stoma preventing aspiration, a second ventilation tube is put in place maintaining the air outlet. A longitudinal incision is made in the middle of the posterior tracheal wall, the length of the fistula. The fistula is circumscribed in benefit of the tracheal layer and the esophageal mucosa is separated from the tracheal epithelium (Fig. 2). An inverted holding suture with a resorbable monofilament (Monocryl 0000) is put in place both at the cranial and caudal end of the fis-

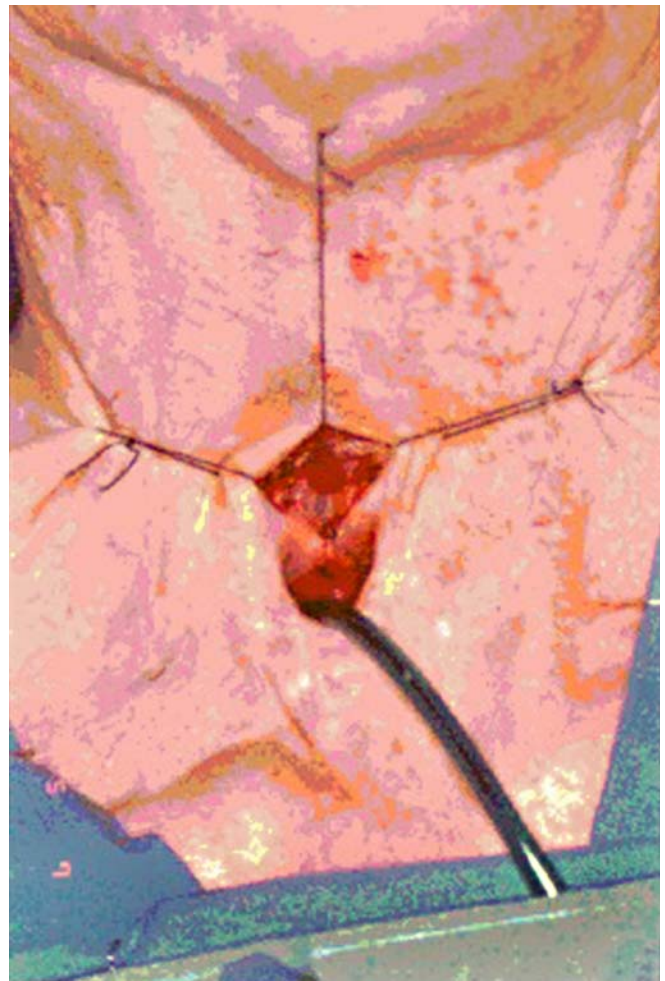

**Fig. 4** Closure of the second esophageal layer



**Fig. 5** Closure of the tracheal epithelium, separated non-inverted sutures

tula. The first esophageal mucosal layer is closed by separate inverted resorbable sutures, paying attention not to strangulate the tissues (Fig. 3). The second esophageal mucosal layer is also sutured by separate inverted sutures (Fig. 4). The third layer consists of tracheal epithelium and is sutured with non-resorbable monofil-



**Fig. 6** Intra-operative view: excision of the fistula

ament (Ethilon 0000; Figs. 5, 6). The dressing consists of a tracheal canula for 3 days. Antibiotics were not administered.

## Results

All patients were operated on by two surgeons (MM and HV) with the standard surgical technique described above. All but two patients received radiotherapy before TE fistula closure. In 6 out of 12 patients (50%) there was perfect wound healing with an immediate surgical success. In the other six patients a period of postoperative leakage illustrated slow wound healing. All of these patients had received radiotherapy. In one patient (P1) the fistula closed spontaneously, albeit after a period of leakage (21 days). Another patient (P9) preferred a new voice prosthesis in the residual opening. Four patients (33%) needed secondary surgical reconstruction with (free) tissue transfer for permanent fistula closure (Table 2). No severe complications occurred.

The mean hospital stay was 18 days (3–43 days). However, the hospital stay is not exclusively linked to the wound healing. The reasons for a prolonged hospital stay

**Table 2** Results. *Surgeon* initials of the surgeon who performed the operation, *date of closure* date of operation, *preop RT* preoperative radiotherapy, + radiotherapy before the closure procedure, - no radiotherapy before the closure procedure, *leakage stop at day* the period of leakage when drinking, *sec surgery* leakage continued and a second surgical procedure was needed to close the fistula, *immediate* leakage stopped immediate after surgery (tested the morning after), *oral feeding* the day when or after which oral

feeding was resumed, *wound healing* the perception of wound healing by the surgeon rated on edema, color (inflammation), *slow* edema and redness present, *good* edema and redness absent, *second surgical procedure* date and kind of procedure, if needed, *FRFF* free radial forearm flap, *pec maior* major pectoral myocutaneous flap, *dysphagia after TE closure* swallowing problems when thoroughly questioned

	Surgeon Date of closure	Preop RT	Hospital Stay in days	Leakage Stop at day	Oral feeding	Pneu- monia	Wound healing	Second surgical procedure	Dysphagia after TE closure
1	M.M. 07/02/00	+	14	21	9 days	No	Slow	None	No
2	M.M. 27/10/99	+	21	Sec surgery	>14 days	No	Slow	(04/01/00) FRFF	No
3	M.M. 14/7/99	+	5	Sec surgery	>14 days	No	Slow	(01/09/97) FRFF (05/10/99) pec maior	No
4	M.M. 4/10/99	-	8	Immediate	7 days	No	Good	None	No
5	H.V./M.M. 21/10/98	+	3	Immediate	2 days	No	Good	None	No
6	H.V./M.M. 29/05/97	+	43	Sec surgery	>14 days	No	Slow	(18/07/97) pec maior	No
7	M.M. 14/01/99	+	8	Immediate	10 days	No	Good	None	No
8	H.V./M.M. 05/02/98	-	19	Immediate	6 days	Yes	Good	None	No
9	M.M. 03/11/98	+	6	14	>14 days	No	Slow	New prosthesis	No
10	H.V./M.M. 24/02/97	+	36	Immediate	10 days	No	Good	None	No
11	M.M. 04/10/99	+	38	3	>14 days	No	Slow	25/10/99 FRFF	No
12	H.V./M.M. 4/11/97	+	12	Immediate	2 days	No	Good	None	No

were diverse, e.g., for patient 6 the hospital stay was prolonged because the patient was not willing to leave the hospital in between two surgical procedures; for patient 10 the hospital stay was prolonged because of psychosis.

Oral feeding was started up to the 14th postoperative day in seven patients (58%); in five patients (42%) oral feeding was started after the 14th postoperative day. This concerned the four patients who needed a secondary surgical procedure and the one patient in whom the fistula was obliterated with a new prosthesis.

## Discussion

The surgical procedure we describe is technically a simple procedure and has an immediate success rate of 6/12 (50%) and a total success rate of 7/12 (58%). Four patients (33%) needed a secondary surgical procedure. In one patient (8%), the residual opening was obliterated with a new button.

Recently, a similar procedure has been described by Hosal and Myers [8]. They performed this technique in nine patients, of which eight were successful. The one failure was dedicated to radiotherapy. In our series, the two not irradiated patients had a sound wound healing resulting in an immediate success. Vice versa, we observe that all patients with a slow wound healing had received radiotherapy. Considering the irradiated group (10 patients), 4/10 healed primarily, 1/10 healed secondarily and 4/10 needed a secondary surgical procedure. The last patient (P9) received a new prosthesis in the residual fistula. This suggests and confirms the findings of Hosal et al. that radiotherapy may have a negative influence on wound healing.

Rosen et al. report a success rate of 13/14 (92%) and state that radiotherapy does not adversely affect the closure rate

[9]. They use a three-layer closure with additional tissue (dermal graft) in between the esophageal mucosa and the posterior tracheal wall. Their technique is similar to the technique of Annyas et al. but has the advantage of avoiding a supplementary skin incision and thus decreases morbidity [10]. Matching success rate and technical simplicity is a challenge in primary tracheo-esophageal fistula closure. Our surgical procedure is simple and easily feasible technically. It consists of a three layer closure, firstly of the esophageal mucosa (two layers) and secondly of the tracheal epithelium (third layer). However, in irradiated patients the success rate turned out to be rather low. Therefore, we are convinced that primary closure of tracheo-esophageal fistulae may only be preferred as a first surgical act because of its simplicity and effectiveness in patients who have not received radiotherapy treatment. This is illustrated by (1) the immediate success in two patients in our series who were not irradiated and (2) Hosal's report [8].

None of our patients mentioned swallowing impairment postoperatively. This means that although the pharyngeal diameter is anatomically reduced, the smaller diameter seems not to affect functional outcome. No doubt this is due to the elasticity of the esophageal mucosa. Because of the fact that the tracheal epithelium is more rigid, performing the circumcission towards the esophageal lining as much as possible, thus providing more tissue at the tracheal layer, enables fistula closure. Apparently, performing the circumcission in favor of the tracheal lining does not result in swallowing impairment.

We started oral feeding up to 14 days in 58% of the patients and even up to 2 days in two patients. This suggests that a meticulous suture, even on esophageal mucosa, can resist mechanical stress, and regular (mechanical soft) food can be administered without additional risk on fistula

recurrence. As such, and compared to the nasogastric feeding period of 7 days described by Rosen et al., this surgical technique may provide a shortening of the nasogastric tube feeding period. The hospital stay may likewise be reduced.

In a not irradiated patient population, this simple surgical technique may (1) provide a good success rate, (2) enable early oral feeding and (3) allow a short hospital stay, thus increasing the patient's comfort. We believe that because of its simplicity, this technique may be considered as the initial surgical procedure for tracheo-esophageal fistula closure, on the condition that wound healing is not compromised by radiotherapy.

## Conclusion

Primary closure of TE fistulae is feasible with a simple technical procedure and may allow early oral food intake and a short hospital stay in patients who have not received radiotherapy treatment. In case radiotherapy has been given, the success rate is only 50% and secondary surgery is needed in 33%. However, the simplicity of the procedure makes considering this technique as the initial surgical treatment in a selected patient population worthwhile.

**Acknowledgements** We would like to express our gratitude to F. Cotman and P. Wallaert for preparing the figures.

## References

1. Brasnu D, Pages JC, Laccourreye O, Jouffre V, Monfrais Pfauwadel MC, Crevier Buchman L (1994) Results of the treatment of spontaneous widening of tracheo-esophageal punctures after laryngeal implant. *Ann Otolaryngol Chir Cervicofac* 111:456–460
2. Remacle MJ, Declaye XJ (1988) Gax-collagen injection to correct an enlarged tracheoesophageal fistula for a vocal prosthesis. *Laryngoscope* 98:1350–1352
3. Ward PH, Andrews BC, Mickel RA, Hanson DG, Monahan GP (1988) Complications of medical and surgical approaches to voice restoration after total laryngectomy. *Head Neck Surg* 10 [Suppl II]:S124–128
4. Blom ED, Hamaker RC, Freeman SB (1994) Postlaryngectomy voice restoration. In: Lucente FE (ed) *Highlights of the instructional courses*, chap 1. Mosby Year Book, St. Louis
5. Delaere PR, Delsupehe KG (1994) Closure of persistent tracheoesophageal fistula after removal of the voice prosthesis. *Laryngoscope* 104:494–496
6. Siu KF, Wei WI, Lam KH, Wong J (1985) Use of pectoralis major flaps for repair of tracheo-esophageal fistula. *Am J Surg* 150:617–619
7. Cunha-Gomes D, Kavarana NM (2001) The surgical treatment of postlaryngectomy pharyngocutaneous fistulae. *Acta Chir Plast* 43:115–118
8. Hosai SA, Myers E (2001) How I do it: closure of tracheo-esophageal puncture site. *Head Neck* 23:214–216
9. Rosen A, Scher N, Panje WR (1997) Surgical closure of persisting failed tracheoesophageal voice fistula. *Ann Otol Rhinol Laryngol* 106:775–778
10. Annyas AA, Escajadillo JR (1984) Closure of tracheoesophageal fistulas after removal of the voice prosthesis. *Laryngoscope* 94:1244–1245